

(THE QUINTESSENCE, Vol.29, No.5/2010-1142, JAPAN)

Intensive course in 2 serials

Denture functions with movement – How to make a stable denture Part 1. The 3DCT images of an edentulous patient and its movement



Yoshihiro Saito, DDS., PhD..

Kunimino Saito Dental Clinic,

4-2-1 Kunimi, Aoba-ku, Sendai-shi, Miyagi-ken
981-0943, Japan

Introduction

As our skills of denture construction become improved, we have a chance to make a maxillary denture with good suction; “Even a patient cannot remove it”. The author once believed wrongly that, as long as a denture was retained with surprisingly good suction like this, a denture would not be mobile and it would work well in good chewing function.

A denture is, however, constructed on the soft nature of the mucous membrane, and so it cannot help mobile more or less from applied chewing force even in a fully retained suction denture. If a patient is asked to simulate chewing with a cotton roll, then the denture is mobile and looks hurting and stimulating the easily injured areas of maxillary tuberosity and mandibular mylohyoid line. It is a matter of course for the author to be well aware from experience in case of mandibular denture that a denture does move even if suction is attained. But the author must admit that it took a long time to understand the necessity of well-disciplined mind and to pay careful attention to mobile behaviors of complete dentures in the maxillo-mandibular jaws.

In this article, therefore, a discussion will be focused on shapes of residual ridges and dentures being photographed by the 3DCT images taken from an identical patient who is examined about residual ridges for complete denture therapy or alternatively for an implant therapy. Furthermore, in these two articles of serials, a discussion will be addressed to what the movement of complete denture really means while being seated on the mucous membrane and what the movement really means when it is successfully minimized.

Discussion on a complete denture patient using the 3DCT images

In this serial, a study patient was an edentulous, 76-year-old female who visited us complaining chiefly about loose fitting of her mandibular complete denture, after her dentures had been constructed by us 4 years before. Checkup of ridges and denture condition by using a tissue conditioning material (Tissue Care, Tokuyama Dental Corp) revealed that it was thicker in the crest of residual ridges, suggesting progressive bone resorption on the ridge crest (**Fig.1a~d**). “GALILEOS” from Sirona Dental Systems was used for CT photographing.

About a patient in this research_____

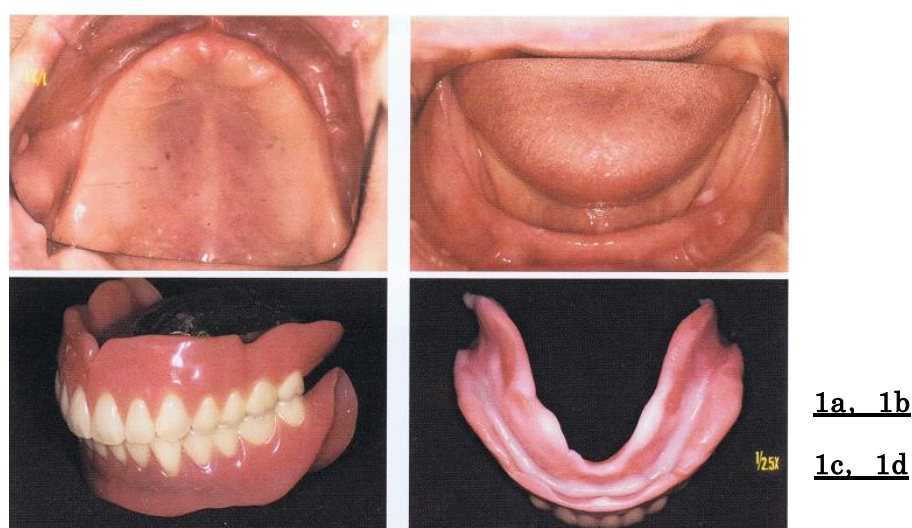


Fig. 1a~d. 76-year-old female patient. New upper and lower dentures were made 4 years before. She visited with her complaint of loose denture which was tested with a

tissue conditioner. Thickness was confirmed especially in the crest of residual ridge.

1. Decreased entire bone volume including the cranium

In the beginning, the 3DCT images were taken including the cranium, and decreased entire bone volume was found, although the trabecular bone that composed of eye socket, cheekbone and nasal aperture were intact in shapes. In the maxilla, bone density was lower than in the mandible, and the cortical bone was turned out to be extremely thin (**Fig.2a~c**).

One of considerations on complete denture patients by CT images

Part 1. Totally decreased bone volume including the cranium _____

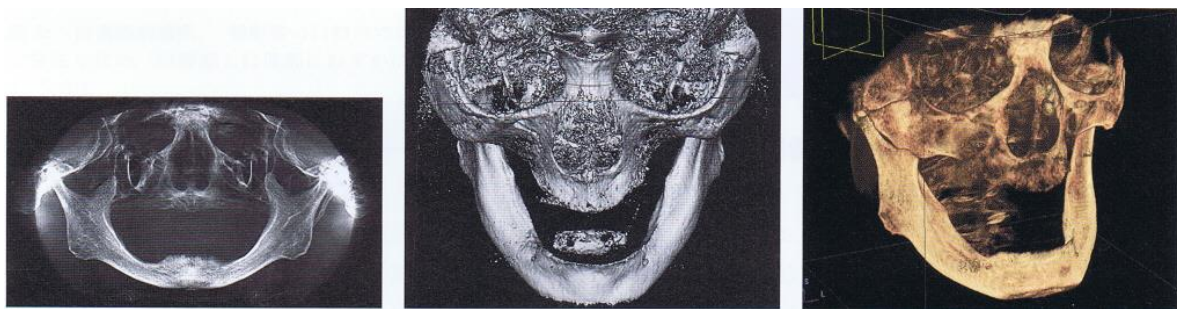


Fig.2a~c. The 3DCT panoramic image by “GALILEOS” from Sirona Dental Systems (a), Surface rendering image (b), and Volume rendering image (c). It is known that the upper face bone volume is decreased. Bone density in the maxillary bone is lower than in the mandible.

2. Ridge mucosa and bone shape are not identical

The mandibular cross section image showed a plate-like residual condition from the anterior median region to the canine tooth and flattened in the posterior region (**Fig.3**). Labiolingual thickness of the ridge crest in the anterior region was observed from the oral cavity examination, but still the 3DCT image of bone crest showed extremely thinner labiolingual thickness with highly advanced resorption.

And the alveolar mucosa in the posterior region was observed in a cord-like ridge

mucosa, but the image of bone morphology showed only a trace level of bone and it was flattened.

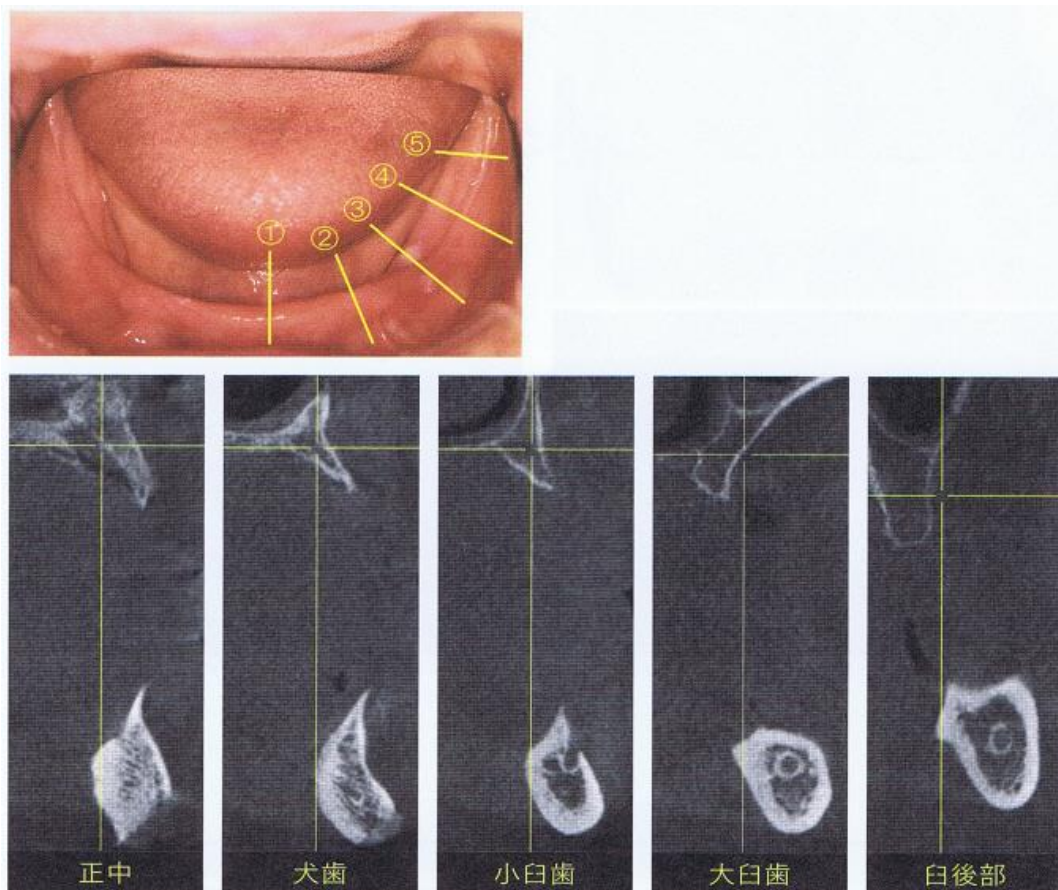
Alveolar crest is thinned in the anterior region and its bone resorption is more progressive with aging hereafter. And, if an unreasonable force is applied even for a second, small bone fracture may occur. Even if a clinical examination confirms a favorable denture, there is a complaint of sudden pain in this region occasionally. In such a case some kind of relation is possible with this finding of small bone fracture.

One of considerations on complete denture patients by CT images

Part 2. Ridge mucosa and bone shape are not identical_____

3a

3b,3c,3d,3e,3f



①Median ②Canine tooth ③Premolar tooth ④Molar tooth ⑤Retromolar region

Fig. 3a~f. CT cross section images over upper and lower jaws. Yellow line refers to coordination of the cross section in the mandible. Section per tooth region (b~f). The

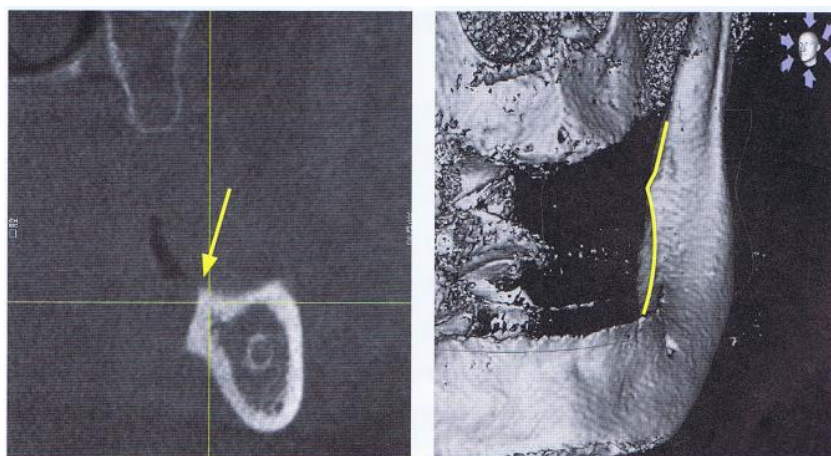
anterior ridge crest showed a thin and plate-like bone shape contrary to the shape of mucous membrane with labio-lingual thickness as shown in the left images. The posterior region was flattened and the ridge crest was inclined to the lingual side.

3. Posterior residual ridge is the lingual side cortical bone in the mandible

In the past the author understood that the residual ridge in the posterior region was the crest of alveolar ridge bone after tooth loss, but the surface rendering image of this progressive resorption showed that the residual ridge was formed with the lingual side cortical bone of mandibular bone starting from the internal oblique line in the ramus of the mandible (**Fig.4a,b**).

One of considerations on complete denture patients by CT images

Part 3. Posterior residual ridge is the lingual side cortical bone in the mandible__



4a,4b

Fig.4a,b

a: Cross section in the retromolar region

b: Surface rendering image

The ridge crest arrowed in 'a' was connected to the internal oblique line in the ramus of the mandible in 'b', forming the residual ridge with the lingual side cortical bone.

4. Swallowing function in an edentulous patient is fulfilled by change of soft tissues in morphology

When the 3DCT image is photographed without wearing a denture, two holding fixtures of the mental rest and the head rest are employed for convenience, and fixation of the mandible against the cranium is determined by an arbitrary position of patient's tongue. As shown in **Fig.5**, only a limited amount of space in the oral cavity is observed in the median plane sagittal section and in the frontal section of the molar tooth region.

One of considerations on complete denture patients by CT images

Part 4. Swallowing function in an edentulous patient is fulfilled by changes of soft tissues in morphology_____

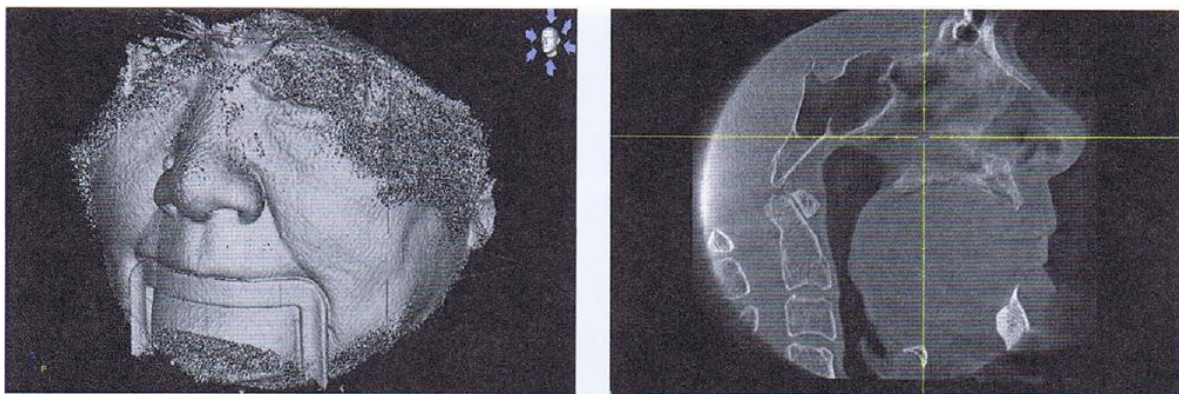


Fig.5a,b. Head rest fixture on imaging. b. Median plane sagittal section.

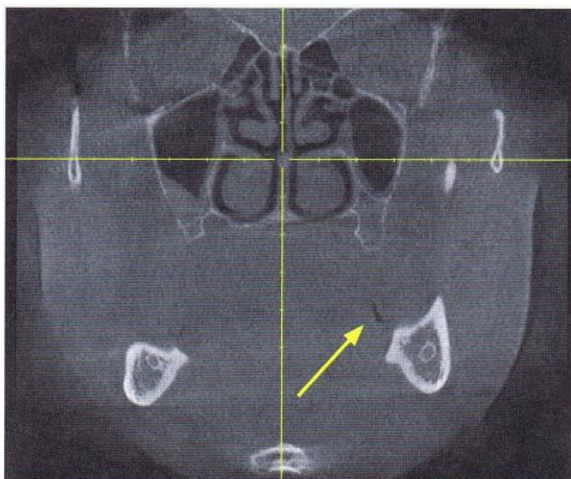


Fig.5c. Frontal section of the posterior teeth region. There is little empty space in the oral cavity on imaging. Only limited small space is seen in the palatal and retromolar regions (arrowed).

Normally, the space of Donders in an edentulous patient is said to be larger than that in a dentate patient. Although the mandibular fixation for the 3DCT imaging is in unusual circumstances, it is already known that the tongue functions to move, when swallowing, to fix the mandibular position and to fill the space to create the negative pressure (**Fig.6a,b**).

In a dentate patient, the mandibular fixation is easily positioned simply by intercuspation of the upper and lower teeth. But in an edentulous patient, the mandibular position is said to be fixed by pinching the tongue and others between the alveolar ridge margins ¹. Also in this case, it is understood that the mandibular fixation was maintained with the tongue and other soft tissues during the 3DCT imaging. The oral photo shows that the soft tissues in the floor of the oral cavity has created the state of, what we call, “Double tongue”, which provides a convenient shape for filling the empty space of the oral cavity (**Fig.7**).

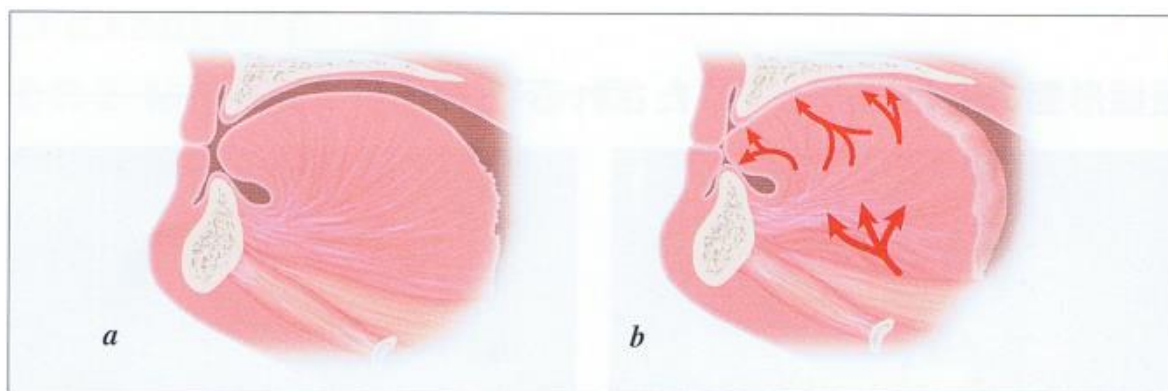


Fig.6a,b. The space of Donders. An edentulous ridge is said to be larger than a dentate ridge (a). When swallowing, the tongue functions to move to fix the mandibular position and to fill the space.

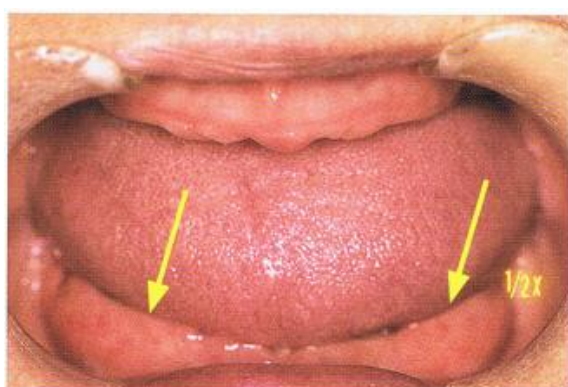


Fig.7. The soft tissues in the floor of the oral cavity looks turned over or, what we call, “Double tongue” (arrowed).

Findings obtained from the 3DCT of denture wearing image

Next, in an object to examine the feasibility of implant therapy, barium powder is mixed with silicone impression material of injection type and the denture imaging was processed (**Fig.8a,b**). For your information, in this case, the denture was with Co-Cr alloy plate, and the imaging agent itself was an image artifact, and so image reading of the maxillary bone was difficult due to minimum bone volume.

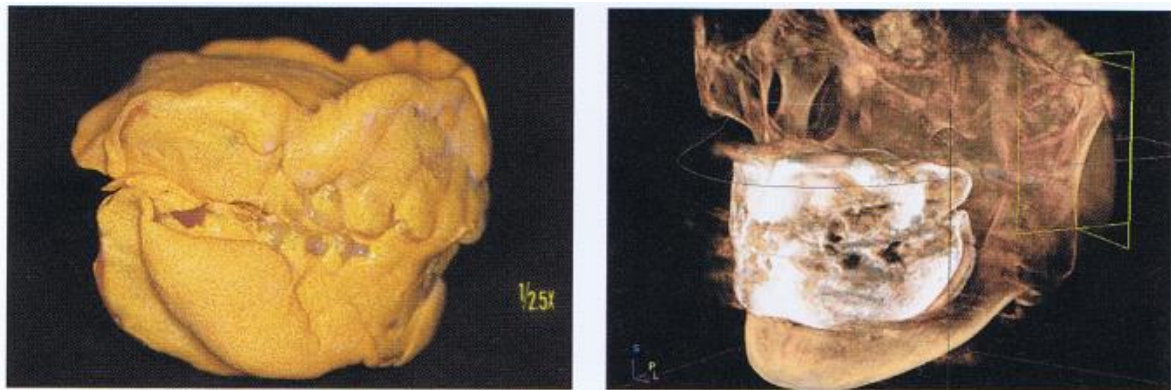


Fig.8a,b. The 3DCT imaging with complete dentures processed. Barium powder is mixed with silicone impression material of injection type and applied (a), and the 3DCT imaging is taken at the intercuspation position of denture teeth to produce the volume rendering image (b).

1. Denture space

When an edentulous patient swallows without wearing a denture, as described previously, lips, buccal mucous membrane, tongue, the mucous membrane of floor of the mouth will change in shapes and will function to fill the space (**Fig.7**). In order to seat a denture successfully into such an oral cavity so that one can wear a denture without sensing of strangeness, a concept of neutral zone is agreeable because it balances the pressures of soft tissues (**Fig.9a,b**).

Findings obtained from the 3DCT of denture wearing image

Part 1. Denture space

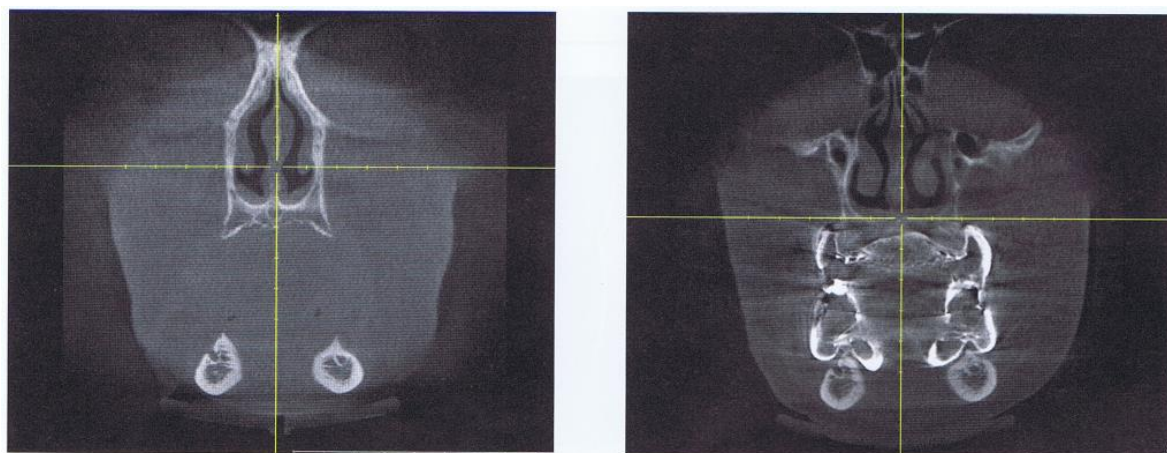


Fig.9a,b. Frontal section image at the mental foramen region. Image without wearing a denture (a), and image with wearing a denture (processed image) (b).

2. Denture floats on the mucous membrane

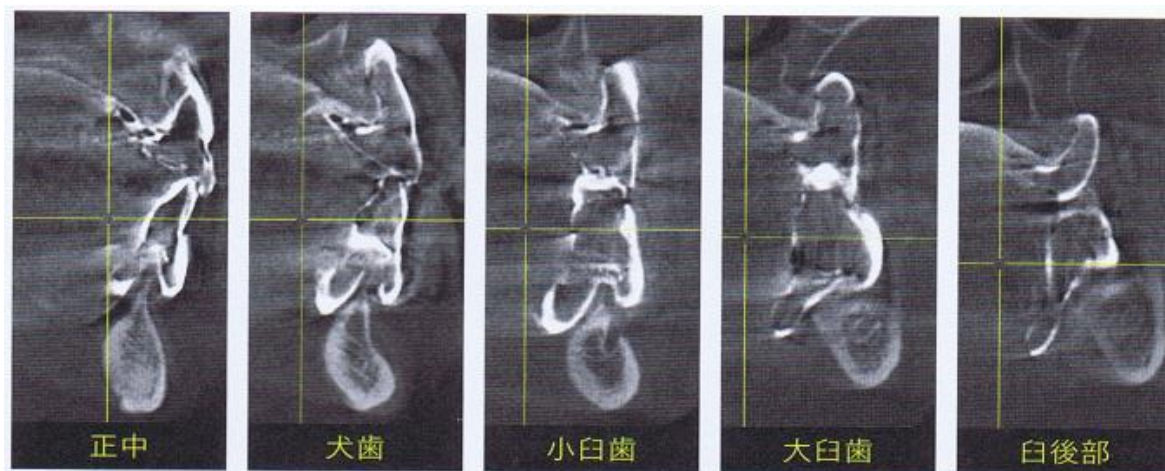
In the maxilla, the distance between a denture base and bony tissues, or the thickness of soft tissues, were varied from different regions. Thinness was confirmed around external surface of the maxillary tuberosity, the ridge crest and the labial side in the anterior region. And on the palate area, the median and anterior areas were thinner, but thicker in the posterior region where displacement of the mucous membrane under pressure was larger and the provision of post dam was acceptable and advantageous.

Meanwhile, in the mandible, soft tissue thickness was thinner and difference of thickness was comparatively small. It was especially thinner in the mylohyoid line area and was matched with the clinical findings that pain developed easily in this region. Also the denture peripheral border in the posterior region did not reach the external oblique line. The buccal muscle was present externally over this region, and so this denture border design was thought impossible to extend.

As a matter of course, soft tissues were present between the denture base and bony tissues as observed all through the cross sections, and the denture was seen floating on the mucous membrane (**Fig.10**).

Findings obtained from the 3DCT of denture wearing image

Part 2. Denture floats on the mucous membrane



a,Median b,Canine tooth c,Premolar tooth d,Molar tooth e,Retromolar region

Fig.10a~c. Cross section at wearing a denture (processed image). Cross section images at approximately same position as in Fig.3. Soft tissues are present between the denture base and ridge, and the denture is again confirmed floating on the mucous membrane.

All dentures move

1. Functional pressure moves a denture

It has been clearly defined from the findings of the 3DCT as previously described that a denture floats on the mucous membrane. Even if a denture is made precisely, it is inevitable to be displaced on the mucous membrane from applied functional pressure. In short; “All dentures do move”.

Watt depicted a schematic by an analogy explaining about a plate floating on the water as a denture and humans as functional pressure (**Fig.11a**). Once a greater force is applied at one end, a denture will be overturned, and so, he explains, the peripheral border must be shaped resistant against the overturn (**Fig.11b**) ². What is most remarkable is that his demonstration is based on an assumption that a denture is mobile.

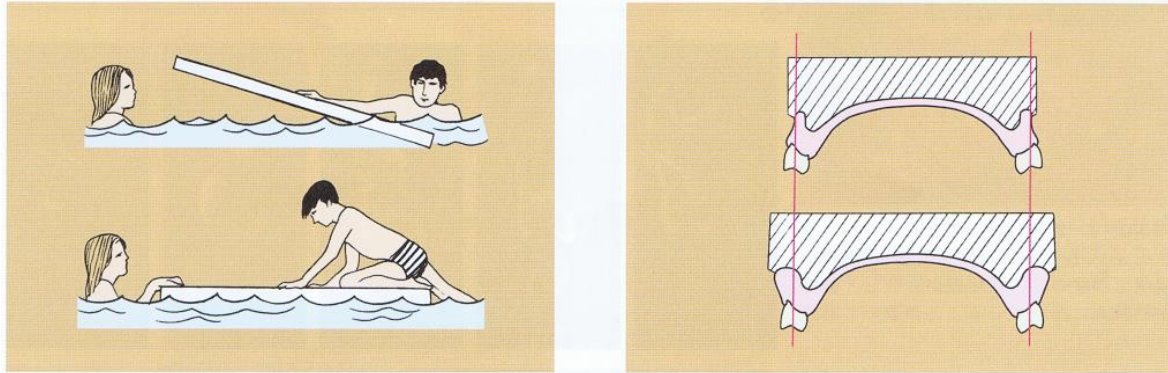


Fig.11a,b. Watt's setup method of teeth and shapes of denture. As in 'a', a plate floating will not be overturned if any force is applied on the other end. In case of denture, a denture overturn will be controlled by the peripheral border (quoted from reference no.3). What is most remarkable is that his demonstration is based on an assumption that a denture is mobile.

2. Know about movement of denture by differences on an articulator and in the mouth

Comparison was made between on an articulator and in the mouth when a wax denture was tried (**Fig.12a,b**). When a cotton roll was tried for a bite on the right side, no contact was made on the articulator on the left side upper and lower posterior denture teeth (**Fig.12a**), but in the mouth on the balancing side there was a contact between upper and lower denture teeth (**Fig.12b**). This kind of denture behavior was made more clarified, when simulated movement is advised to chew a cotton roll at several times and crash it hard in the mouth.

This behavior suggests how the dentures are moved and displaced on the oral mucous membrane in the maxillo-mandibular jaws. Even how much a denture is made in precision and in effective suction, it is very natural that displacement is created under functional pressure.

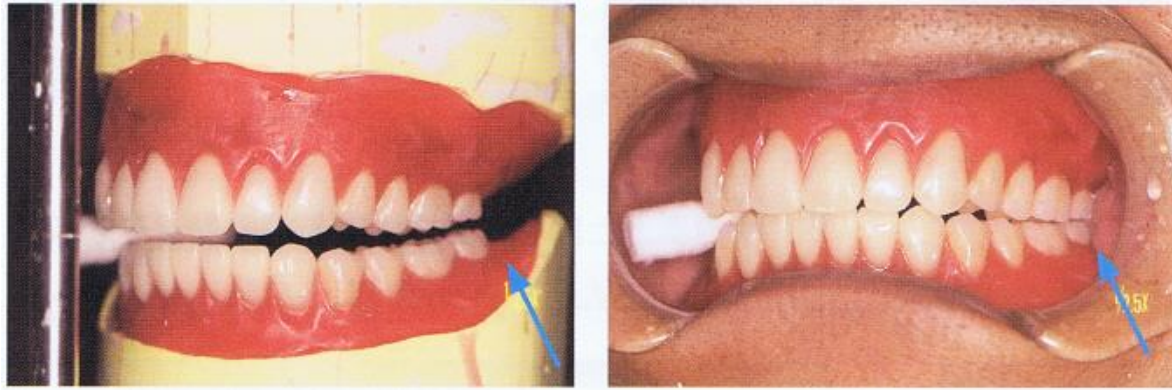


Fig.12a,b. Differences of an identical wax denture between on an articulator and in the mouth. When a cotton roll is bitten in one side on an articulator, disclusion is observed in the non working side (a), and as denture teeth contact in the non working side is seen in the mouth, it is understood that a denture is displaced (b).

3. How does a denture move?

A fit checking paste was applied on the mucosal surface of a denture and waited for setting with a cotton roll chewed on the right side (**Fig.13a**). Thickness of the fit checking paste showed thinner on the working side, and thicker on the balancing side. In the maxilla, especially thinner at the tuberosity on the balancing side, and a horizontal rotation was observed accordingly as the denture sinks (**Fig.13b**). In the mandible, too, sinking on the working side and lifting on the balancing side were observed. Thinner part was seen lingual on the balancing side, and a horizontal displacement was confirmed (**Fig.13b**).

From the observation above, major denture movements on the mucous membrane are summarized as follows;

- ① Sinking
- ② Lifting (Rotation on the frontal plane with ① and ②)
- ③ Rotation on the horizontal plane
- ④ Displacement (Horizontal translation)

Denture displacement is considered possibly caused by these movements above in complex manners simultaneously (**Fig.14**).

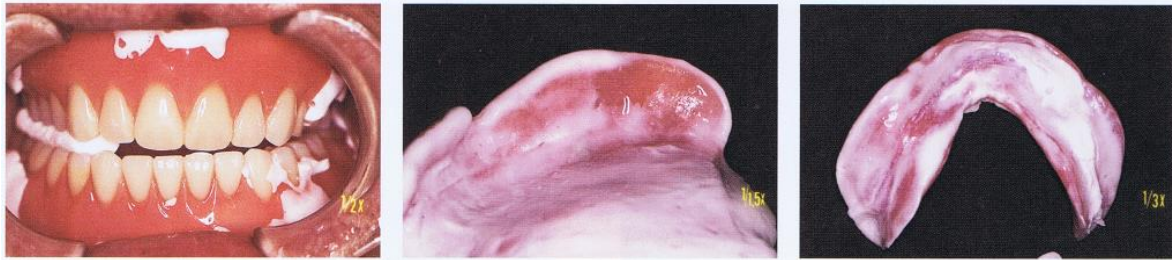

Fig.13a~c. A fit checking paste was left set with a cotton roll chewed on one side (a), denture sinking and displacement was observed in the area of maxillary tuberosity (b). In the mandible, sinking on the working side, lifting on the balancing side and denture rotation were seen (c).

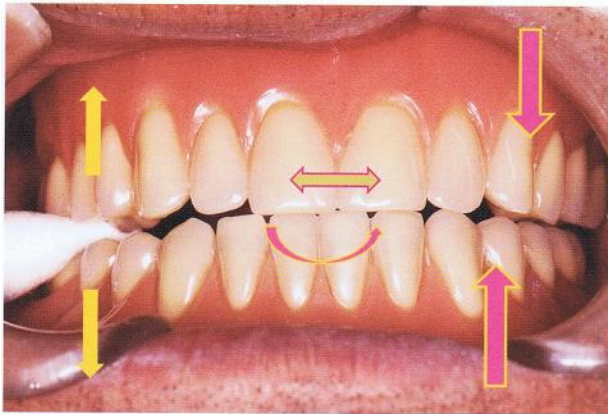


Fig.14. A denture in the mouth is displaced in complex and simultaneous manners through sinking, lifting, displacement, and rotation (horizontally).

4. How much does a denture move?

It is known that a denture is displaced on the mucous membrane by the functional pressure, but how much would the movements be displaced in practice? As far as a denture movement is concerned, it reminds us very immediately of the mucous membrane resiliency under pressure ⁴. In their research study Ono et al. ⁵ reports on the mucous membrane resiliency under pressure of about 200~300 μ m with the pressurized surface area of 20mm². Meanwhile, if actually simulated chewing of a cotton roll is tried in the mouth, a denture movement can be confirmed visually. And it is easily understood that this amount of resiliency in about 0.3mm does not mean immediately the amount of denture mobility.

Miyashita ⁶ reports on denture mobility and its inclined angles using the motion capture system (a detection method of three dimensional movements). The maxillary denture mobility shows 0.78mm at a maximum during tapping and larger than the value of resiliency of the mucous membrane under pressure.

And maximum denture mobility when chewing was 1.32mm with inclination of 3.46° in the maxilla and 4.11° in the mandible (**Fig.15**). Although no denture mobility in the mandible was mentioned, the absolute value of denture mobility must have been larger than that of maxilla, if considered clinically. Consequently it is understood that denture mobility when chewing will occur simultaneously between maxillo-mandibular jaws, and that denture will be repeatedly displaced in greater amount than the resiliency of mucous membrane under pressure (**Fig.16a,b**). If a denture is not fit well with repeated frequency of unreasonable mobility, it cannot help inducing unnecessary ridge resorption. Larger amount of denture mobility will induce consumption of the biological cost (the biological compensation).

Resiliency of mucous membrane under pressure and denture mobility⁵ _____

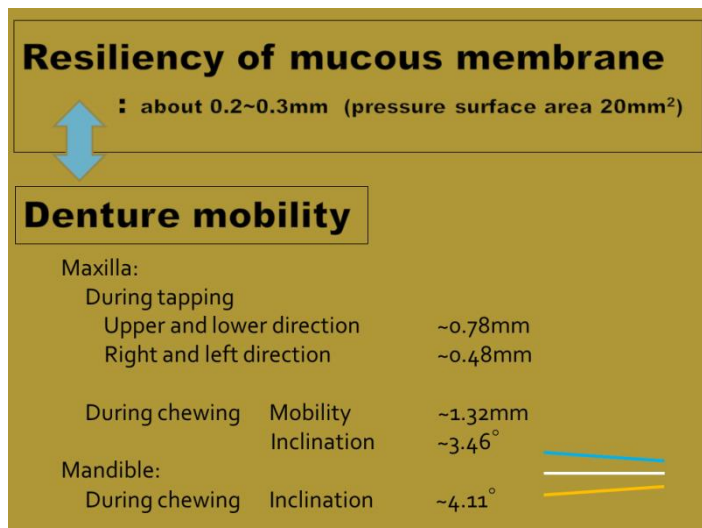


Fig.15. Denture mobility is not the resiliency of mucous membrane under pressure. Blue

line in the figure shows an inclination of maxillary denture, green line an inclination of mandibular denture, and purple line indicates horizon.

Denture mobility occurs simultaneously between maxillo-mandibular jaws, and displaced repeatedly in greater amount than the resiliency of mucous membrane. _

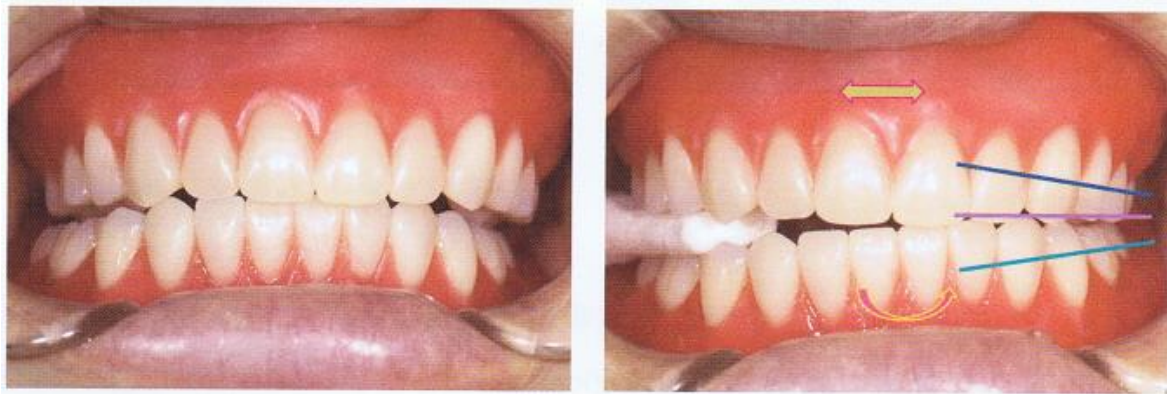

Fig.16a,b.

a: Bilateral balanced occlusion of the right lateral movement in the empty side

b: While in chewing, the denture moves. Contact on the balancing side is made and bilateral balancing is attained.

5. Traces in that a denture still moves based on clinical observation

Some discoloration of tea tannin stains or sludged plaque deposits are occasionally found on a denture while in use. It is supposed that, even if a denture is attained with effective suction, saliva containing food pigment or liquid form plaque is permitted to go in and out under the denture base during the pumping action of denture mobility caused by repeated chewing movement (**Fig.17**).

Another problem in our experience is a denture fracture in the median area of maxillary denture or in the area of clasp retainer of mandibular partial denture. This kind of denture fracture is not caused by the resiliency of mucous membrane with the value of around 0.3mm, but is caused by the deflection of denture base loaded from the larger scale of denture mobility than that (**Fig.18a,b**).

It is known that so-called the biological cost is the cost that must be paid for the body to maintain functions. With that in mind, costs of denture quality deterioration and fracture as well as artificial teeth abrasion may be called as the artificial cost (compensation of artificial products to be paid for function).

Denture stains

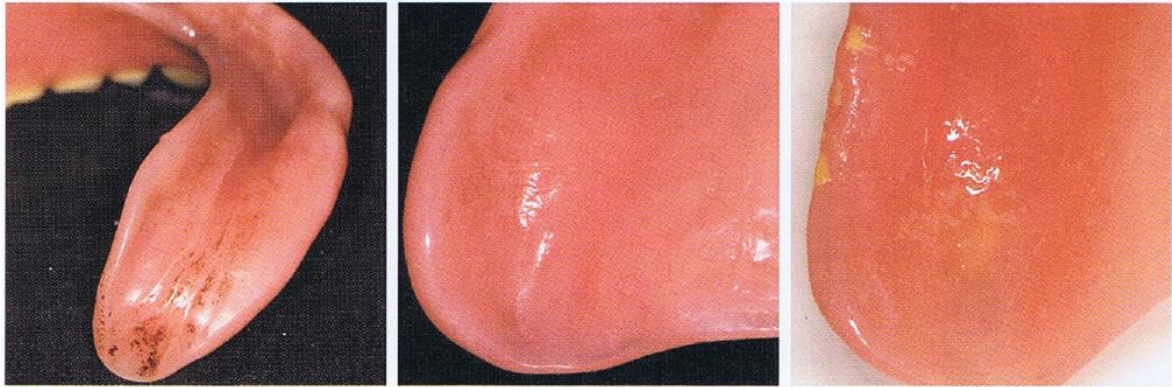

Fig.17a~c. Denture stains may be seen in the inner surface being caused by moving denture.

Causes of denture fractures

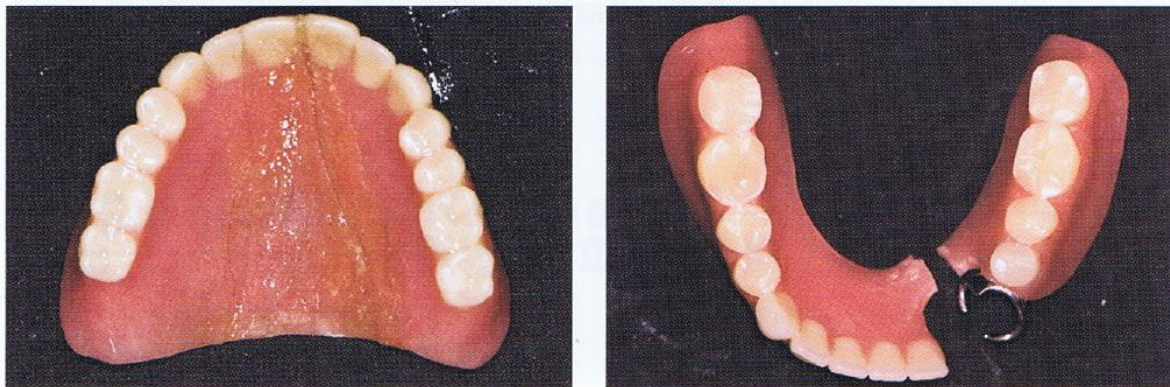


Fig.18a,b. Denture fracture is not caused only by the resiliency of mucous membrane.
a: A maxillary denture is likely to fracture in two parts at the median or at the dental coping that works as fulcrum point.
b: A base fracture and noted denture teeth abrasion are seen, permitting denture deflection under functional loading.

Summary

In this serial as Part 1, relations of edentulous alveolar ridge and denture have been addressed by way of the 3DCT images, and a denture has been shown floating on the surface of mucous membrane. A denture on the whole is mobile to functional pressures

and is displaced from the larger scale of denture mobility than the resiliency of mucous membrane under pressure, and the chewing function may be fulfilled during denture moving.

In the next serial, Part 2, discussion will be addressed to an issue “denture construction with minimum mobility” in pursuit of denture stability while in function. (References will be listed combined in the next part.)

【End of Part 1, to be continued later】

(THE QUINTESSENCE, Vol.29, No.6/2010-1391 JAPAN)

Intensive course in 2 serials

Denture functions with movement – How to make a stable denture Part 2. The Strategy for the Denture Stability



Yoshihiro Saito, DDS., PhD..

Kunimino Saito Dental Clinic,

4-2-1 Kunimi, Aoba-ku, Sendai-shi, Miyagi-ken
981-0943, Japan

Introduction

In the previous part, it has been presented that a denture floats on the surface of mucous membrane and mobility cannot be prevented under function. Now in this article of latter half part, discussion will be addressed to the method of minimizing this denture mobility as small as possible, and will be addressed also to the stability that can be attained through denture movement. To tell the conclusion first, there is no other means but to proceed every phase of denture construction precisely with every precaution. Here in this article major three points of precautions will be especially described, and then, denture stability under function will be demonstrated with clinical case findings.

Denture should not be displaced at the occlusal registration = ICP (Intercuspal Position)

In order to stabilize a denture while in function, it is vitally important to establish a fundamental posture on the mucous membrane⁷. As shown in **Fig.19**, touch the teeth of upper and lower dentures with your finger face, and check if the occlusal registration

has been thoroughly done, and check whether or not there is any discrepancy of displacement or rotation verified in the course of mouth opening to chewing in to the ICP.

As a result, a denture is pressurized evenly on the surface of the mucous membrane and cohesion is attained by interposing air and saliva under the base. This principle is based on similar effect of cohesion made in two layers of glass plates with interposed layer of water and should be discriminated from suction effect¹⁶.

It is known that the occlusal registration is not easy with cases of multiple tooth loss or edentulous patient^{8~13} (**Fig.20**). One must be well equipped with satisfactory clinical skills with good results. Since success of the occlusal registration does influence on the frequency of denture adjustment after insertion¹⁴, a certain amount of satisfied results can be attained for the author by researching the stable and reproducible tapping points from the combination of drawing of Gothic arches and recording the tapping points^{12,13}.

How to coordinate with occlusal registration and denture ICP record..._____

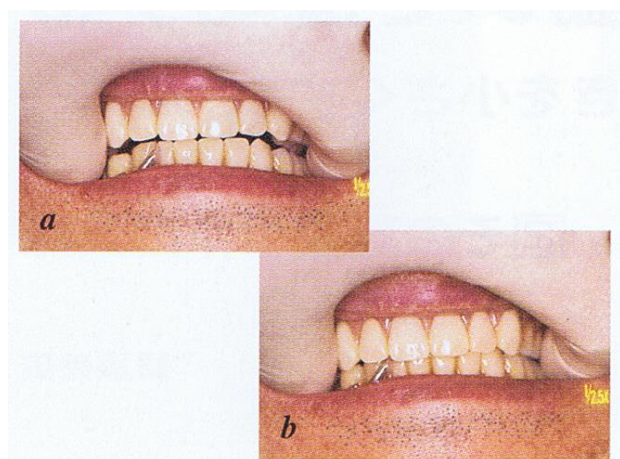
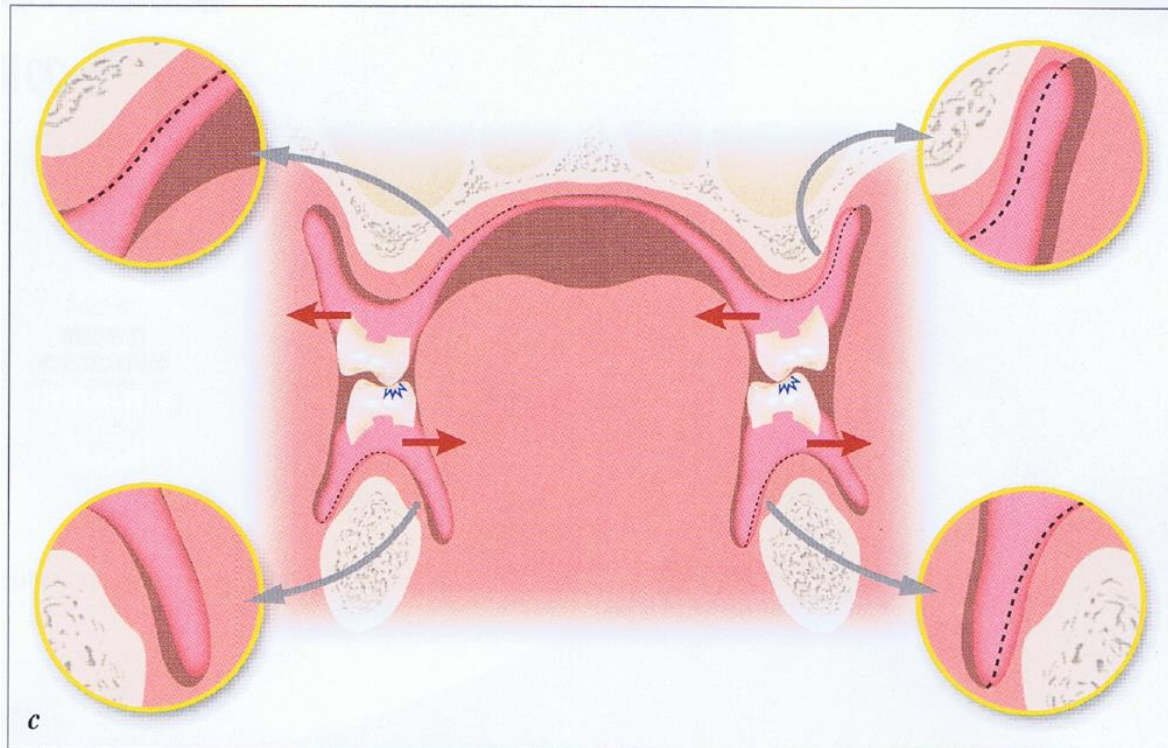


Fig.19a~c. Check the coordination of occlusal registration and denture ICP.

a: Touch with your finger face between the upper and lower denture teeth asking to bite it lightly.

b: Follow the touch sensation with your finger from the contact up to the ICP searching sense of displacement or rotation in the course.



c: Discrepancy of occlusal registration will cause denture mobility (quoted and modified from reference no.7).

It is difficult to take occlusal registration of edentulous patient_____

- Only 10% of subjects that match Gothic arch apex and tapping point.
- 75.6% of them have some mechanical problems involved with TMJ.
- 68.6% of them have some internal derangement of TMJ and frequency of complete denture wearers who have normal TMJ is in small number.
- Changes in morphology of TMJ is significant after tooth loss.

Fig.20. From previous reports so far ^{8~13}, various changes may have been experienced in the TMJ and mandibular position in the course of tooth loss to become edentulous.

Fulfillment of effective suction

1. Retention, bracing and support of complete denture

A partial denture is to be designed taking consideration of retention, bracing and support. And these 3 elements are carefully coordinated to address problems of “lifting”, “sinking” and “rotation” that destabilize a complete denture (**Fig.21**).

Complete denture movement_____

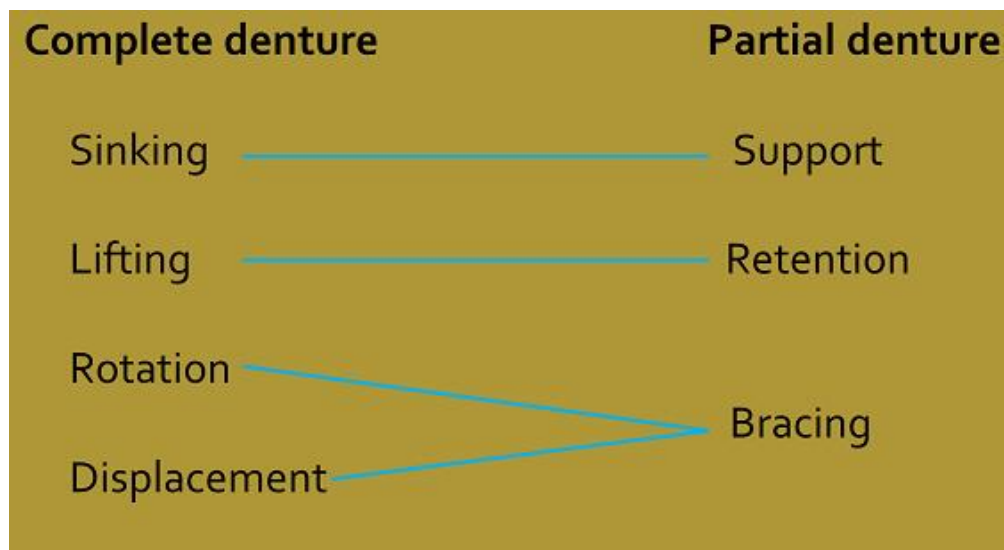


Fig.21. Complete denture movement can be understood in accordance with designing a partial denture.

Since a complete denture is one single unit of base plate, these 3 elements of function will work all together to the residual ridge, tongue and buccal mucosa by way of the base plate. When the cross section of mandibular molar tooth region is taken as an example, the working denture plate could be divided into 4 sections as a whole, and the following reciprocation of A to B, C to D, A to D, and B to C will work for the denture stability ¹⁵ (**Fig.22**).

Bracing will work effectively for resisting to denture displacement in coordination with the denture mucosal surface, buccal surface and peripheral border of each denture. And support will work from the crest of residual ridge to the mucosal surface along the peripheral border, since the denture base is shaped to resist to sinking. If the

sinking on the working side is minimal, the lifting on the balancing side will be prevented and the opposite side is highly retentive (**Fig.23**).

If retention is enhanced after suction is effective, then bracing will be increased. And as the relation of denture and residual ridge will be maintained, this relation will exert further retentive force. In other words, complete denture retention, bracing and support will work all together for denture stability through all the contact surfaces of denture base and mucosa simultaneously, reciprocally, and yet cooperatively. In short, when one or other functions above is enhanced, all these three functions will be enhanced also to increase denture stability.

Retention, bracing and support of complete denture

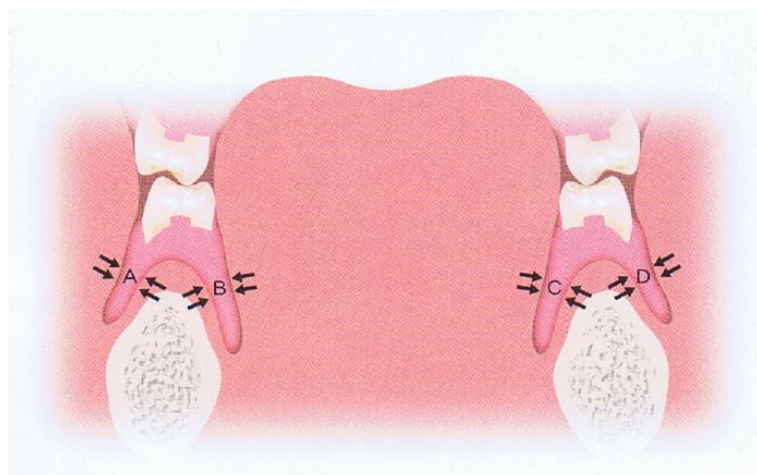
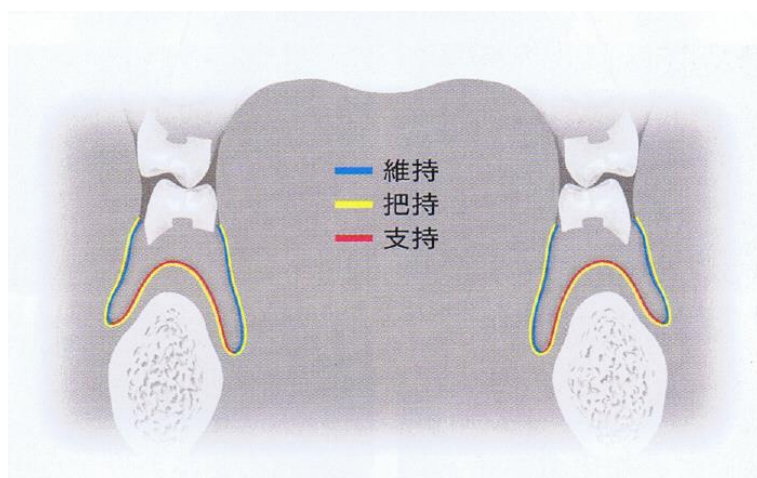


Fig.22. Cross section at the mandibular molar tooth. 4 sections work as reciprocation force ¹⁵.

Retention, bracing and support of complete denture



(blue) Retention
(yellow) Bracing
(red) Support

Fig.23. Major regions involved with retention, bracing and

support. Reciprocation will work in coordination with denture stability.

2. Suction enhances denture stability while in function

A well fit denture produces cohesive force from the mucosal surface at the ICP. And suction is this cohesive force developed in an advanced phase at higher level in order to match the mucosal surface to ridge shapes while in function. Suction mechanism is based on peripheral closure of entire denture base and is to attain entire peripheral closure without going broke even while in function¹⁶.

For this attainment, our target is to take an impression of functional shapes of mucosal surfaces in the closed mouth (**Fig.24,25**), and to provide the denture with three dimensional peripheral margins and shapes of polished surfaces. As described in the previous chapter, that suction force will be enhanced, all the functional forces of retention, bracing and support will be enhanced and will contribute greatly to denture stability while in function.

Preliminary impression taking by the closed mouth functional impression method__

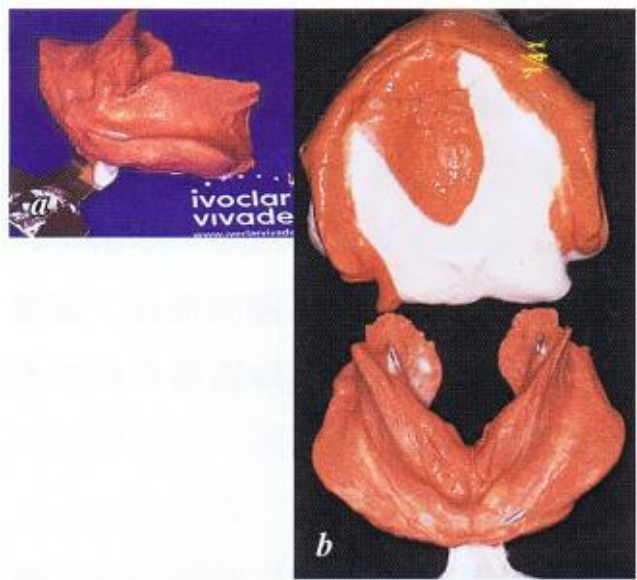


Fig.24a,b. This is an impression made up with Accu-Dent System based on BPS (Ivoclar Vivadent AG) combined together with Frame Cut Back Tray for attainment of

mandibular complete denture with effective suction. Preliminary impression taking by the closed mouth method is an initial step toward suction.

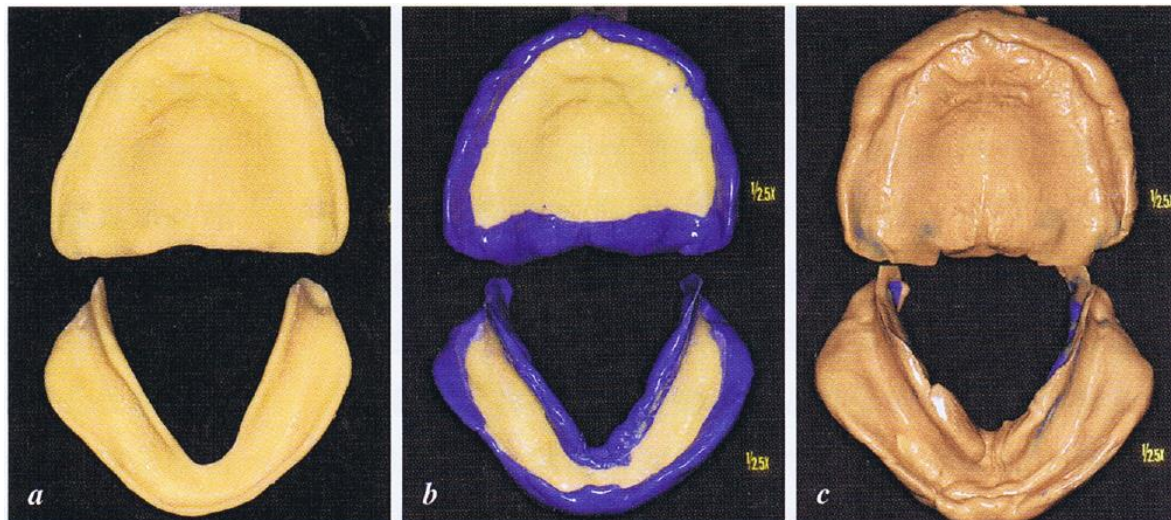


Fig.25a~c. Precision impression with Virtual (Ivoclar Vivadent). From the phase shown in Fig.24, a tray with a rather shorter margin can be made being added with border molding silicone impression material and a functional shape of mucosal surface at the closed mouth is taken.

Occlusal scheme that controls movement

While chewing, its functional pressure will work as vector to move a denture. It is important for denture stability to prevent mobility as much as possible, or alternatively, in case any mobility cannot be prevented, to control mobility as minimum as possible. Now here in the next chapter, clinical interpretation will be reviewed on the occlusal schemes that are classified in textbooks.

1. Unilateral balanced occlusion (Unilateral balance)

Unilateral balanced occlusion means equilibrium that moment vector transferred to a denture through food bolus while chewing does not cause to wobble the denture greatly¹⁷. This kind of equilibrium is dependent on the direction of functional force, setup position of denture teeth, and selection of the teeth.

Practically in clinical case, in order for a patient to be made easy control of the chewing vector better, artificial teeth of lingualized setup are selected and set up a little toward the lingual side¹⁸. This position is acceptable as long as the denture is not

turned over when the denture teeth are tried to push down with your fingers (**Fig.26**).

But precautions are needed as this kind of teeth arrangement with the lingual inclination may cause interference with the tongue space or impingement of esthetics in the maxillary premolar teeth region (**Fig.27**).

Caution needed on premolar or canine teeth regions!_____

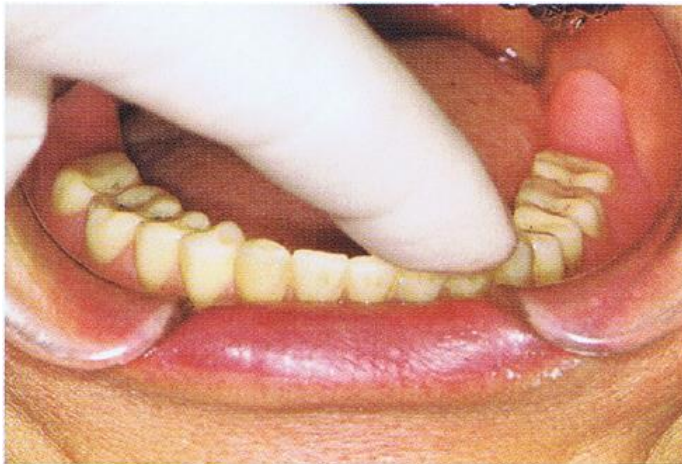

Fig.26. In premolar or canine teeth regions, a denture is likely to turn over as the teeth are arranged externally from the residual ridge.

Teeth arrangement to resist a turnover_____

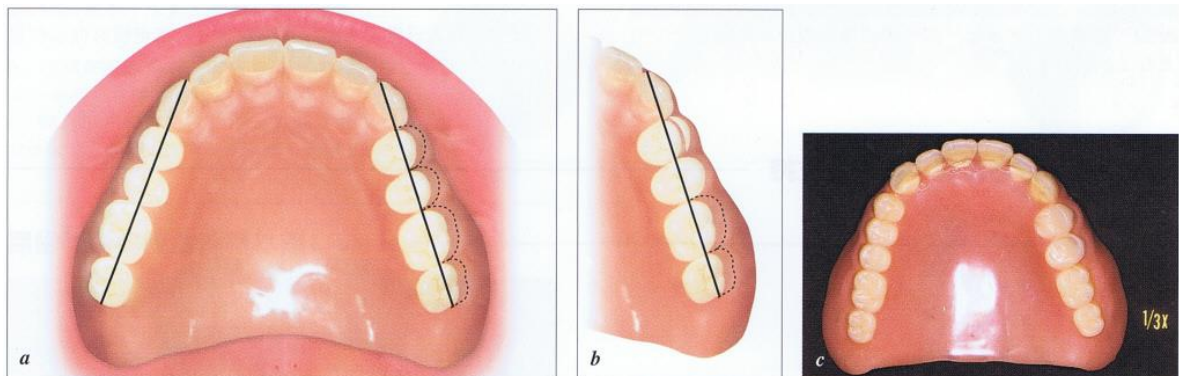


Fig.27a~c. The arrangement should be a little closer to the median to resist a turnover (left). In the premolar region, esthetic disorders or saliva leaking from the oral angle might occur, and so doubled layer of denture labial surface or larger teeth are designed (arrowed). An example case is shown in 'c'.

2. Bilateral balanced occlusion (Bilateral balance)

So far our attention has been made in this article so that denture mobility should be minimized. But, in this chapter, our discussion will be addressed to the situation that unstable condition will be controllable by denture movement and displacement.

Bilateral balanced occlusion that is needed while chewing is obtained through creation of occlusal contacts of upper and lower artificial teeth on the balancing side where a denture is tilted and then lifted after loading of functional pressures on the working side. Ironically unless a denture moves, this kind of left and right horizontal balancing cannot be obtained. So, to minimize and regulate the denture displacement means to become controllable to the movement. This occlusal scheme is bilateral balanced occlusion that makes easy to obtain occlusal contacts on the balancing side.

As an example, in case the teeth are arranged according to the cuspid protected occlusion, the Christensen phenomenon is established on a lateral excursion, and clearance of disclusion cannot help but larger than other schemes. Consequently unless a denture moves largely, occlusal contacts cannot be gained on the balancing side. On the contrary, this scheme of bilateral balanced occlusion has tendency to clear the gap of the disclusion (**Fig.28a**), and so the distance of upper and lower teeth on the balancing side is most approximate and intimate among all occlusal schemes, even when any food bolus is interposed on the working side. After all with this occlusion, denture displacement is very limited, and occlusal contact on the balancing side can be obtained within shorter time (**Fig.28b**).

Bilateral balanced occlusion and bilateral balance_____

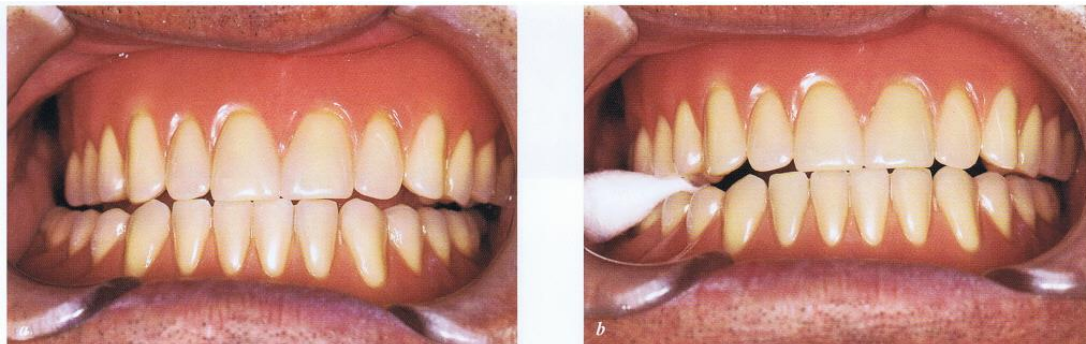


Fig.28a,b. Bilateral balanced occlusion (a) and bilateral balance (b)

a: Posterior disclusion is not present in lateral movement.

b: A cotton roll on the right side (food bolus) and the balancing contact on the left will stabilize a denture. A situation that is balanced bilaterally. Anterior teeth contact is also seen.

Minimal denture displacement while chewing is advantageous for enhancement of chewing efficiency and relief of loading from the mucous membrane and residual ridge. Bilateral balanced occlusion is in general understood as an occlusal scheme at non working time, but practically it is most advantageous occlusal scheme for stabilizing a denture functionally while chewing¹⁸. As an example, a case of teeth arrangement making use of a template and teeth contact situation within the oral cavity will be shown (Fig.29,30).

Artificial teeth arrangement by bilateral balance occlusion using BPS System_____

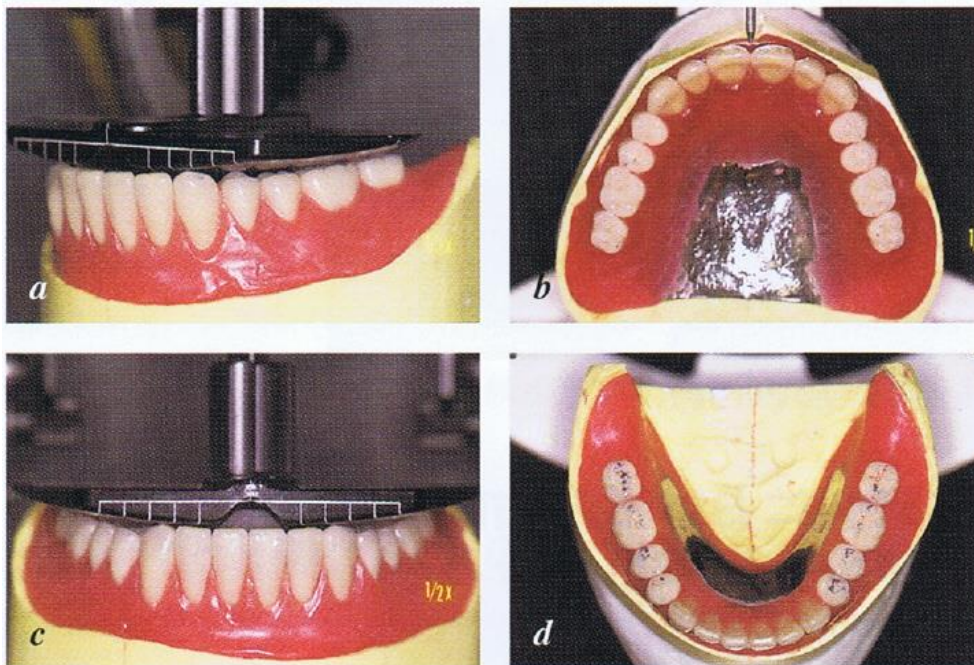


Fig.29a~d. Almost automatically teeth will be set up according to bilateral balanced occlusion, making use of BPS Setup Template.

Complete denture construction is completed in bilateral balanced occlusion using the lingualized artificial teeth_____

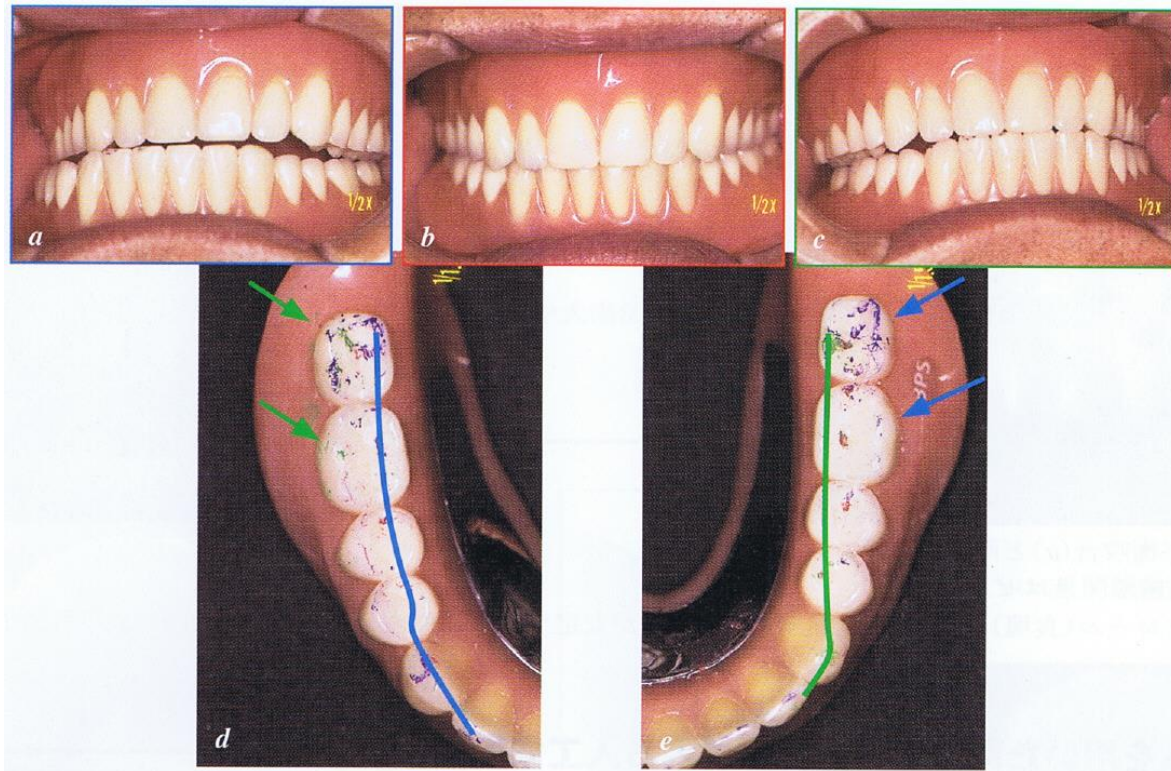


Fig.30a~e. The arrangement was completed as shown in Fig.29. In case of bilateral balanced occlusion using the lingualized artificial teeth, the working side is guided by the lingual cusps internal inclination (solid line) of canine and premolar teeth, and the balancing contact (arrowed) is determined by the buccal cusps internal inclination of molar tooth on the balancing side.

Clinical examples of balancing contact in left and right, anteroposterior situation

1. Bilateral balanced occlusion and full balanced occlusion

Full balanced occlusion is understood as an occlusion scheme with smooth excursion of not only the teeth on the working side but also on the balancing side even including the anterior teeth both in lateral and protrusive translation movements¹⁹. Although interpretation of the term, “full”, is somewhat ambiguous, this might be in the situation that all the artificial teeth are sliding in contact without any disclusion in every eccentric direction.

This occlusal scheme makes easy to gain denture stability while in function by obtaining the balancing contact in left and right, and anteroposterior situation which is antagonized against the working side within minimal denture mobility generated by chewing food debris. As a result, it helps to achieve “the backward chewing with a denture” (Fig.31a,b).

Balancing contact that stabilizes a denture

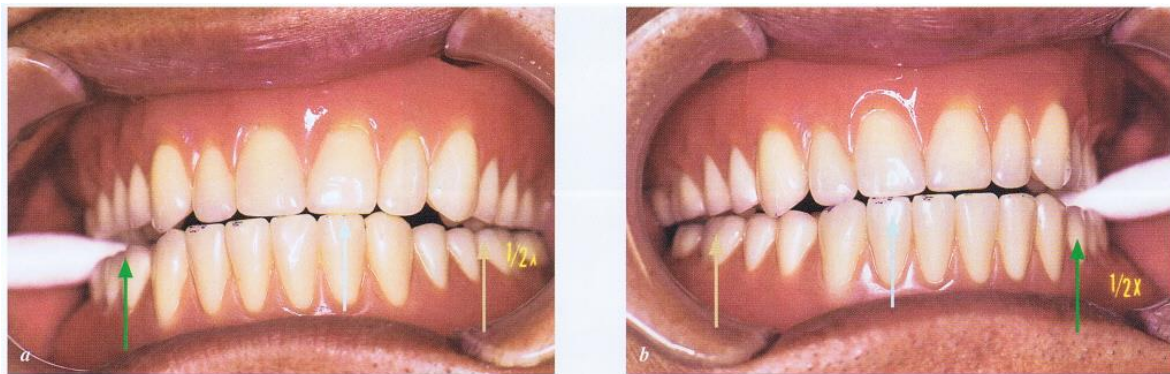


Fig.31a,b. Three-point support is made to stabilize the upper and lower dentures with the food bolus while chewing and the lateral and anterior balancing contact. The green arrow is the support by the food bolus, the light blue arrow is the anterior teeth, and the yellow arrow is the support by the lateral balancing contact.

2. Balancing contact seen in practical case

Denture mobility is seen more often in case of a single denture rather than case of maxillo-mandibular complete dentures. Balancing contact is a kind of stability gained from denture mobility, and in case of a single denture, its movement is more accelerated as this is done with one single denture only contrary to the movement done with those set of upper and lower dentures. So, in order to work out a denture in stable condition, the left and right, and anteroposterior balancing contact is far more effectively needed for better stability.

As shown in Fig.32 of a maxillary single denture, even though some anterior clearance space is present at the ICP, there, in the lingual side of incisal edge of the

upper left first incisor, a shiny facet (mirror polished wear pattern) is detected. This confirms that the tooth contact with the lower left first incisor has been used most (**Fig.32**). This kind of tooth contact may be called as an anterior balancing contact (temporarily called).

Next, as shown in case of a mandibular single denture in **Fig.33**, there also, in the incisal edge of the lower right artificial incisor, a shiny facet again is found, and this confirms that the anterior balancing contact with the right upper first and second incisors is established and used for the denture stability while in function (**Fig.33**).

The lingual side incisal edge of the mirror polished tooth wear facet that works as the anterior balancing contact, Case 1 _____

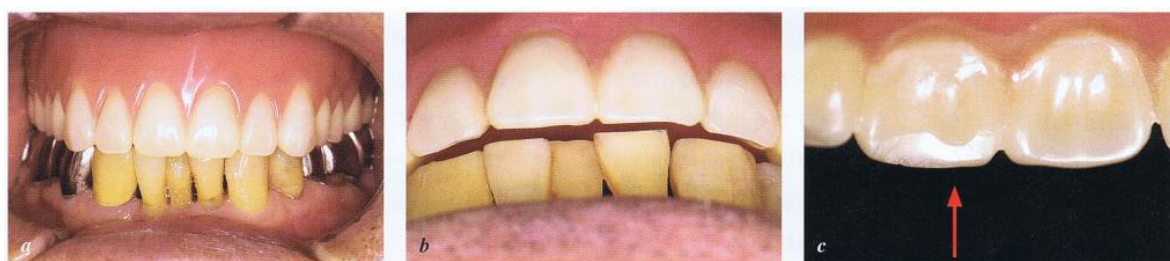


Fig.32a~c. Case of maxillary single denture. No anterior contact is seen at ICP, and on the lingual incisal edge of the upper left first incisor, a mirror polished tooth wear facet is present. It is shown that it is used as the anterior balancing contact (arrowed) while in function.

The lingual side incisal edge of the mirror polished tooth wear facet that works as the anterior balancing contact, Case 2 _____

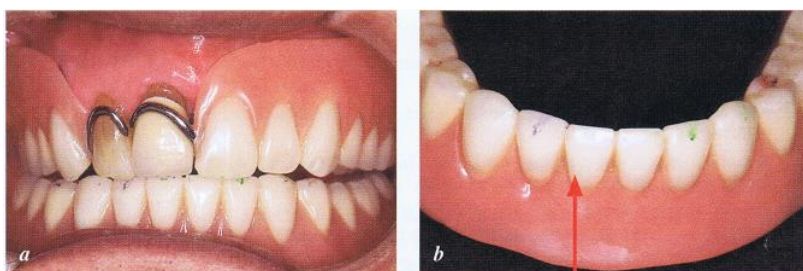


Fig.33a,b. Case of mandibular single

denture. A mirror polished tooth wear facet (arrowed) is present as the anterior balancing contact in accordance to the maxillary remaining teeth.

In clinical case of **Fig.34**, the anterior balancing contact is confirmed on the upper left first and second incisors with the trace of tooth wear on the lingual side applied from the force of inferior lateral direction, and also the lateral balancing contact is seen on the lower right second molar, which suggests positive use of chewing on the left side (**Fig.34**). The balancing contacts above are not generated intentionally by the clinician in order to demonstrate effective advantages, but are generated spontaneously by patient's natural adaptation. What the clinician can present is the provision of all the circumstances where stability can be established more easily by designing necessary anterior clearance space²⁰ as well as bilateral balanced occlusion.

Case where the anterior balancing contact is confirmed in the upper and lower artificial teeth _____

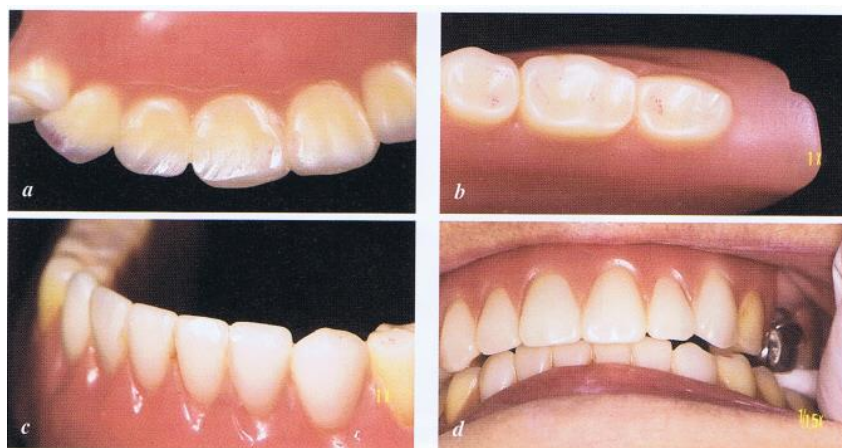


Fig.34a~d. Case where the anterior balancing contact is seen in the upper and lower artificial teeth. The food bolus on the left while in function, and the lateral and anterior balancing contacts are made up as the three-point support and stabilizes a denture while in function.

At the conclusion

In these serials, two different articles have reported that denture mobility cannot be avoided by any means while in function, and, on the other hand, that this mobility can

be used for denture stability. These reports are presented as supplementary of clinical interpretation toward scientific findings obtained from long research history of complete denture study.

All through the ages, edentulous patients wish ardently for denture stability while in chewing function. For responding to that wish, best way should be that ICP must be established properly, effective suction be attained and occlusion be provided with controlled mobility.

Also in case of an implant supported overdenture which has been widespread recently, serious problems will be raised from implant fixtures overloaded by denture mobility. So in such a case, too, denture making should be definitely employed with clear understanding of issues involved with mobility while in function.

Reference

1. Nagle RJ. Sears VH. Denture Prosthetics Complete Dentures (2nd Ed.) Saint Louis: Mosby 1962; 270 – 271
2. Watt MD. Designing Complete Denture. Saint Louis: W.B.Sanders, 1976
3. Matsumoto N. Occlusal schemes of complete denture, Interviewed: Kaneda K. Real significance of complete denture, Tokyo: Quintessence Publ. 2001, 148 (Japanese)
4. Kishi M: Relationship of pressure surface area and displaced amount concerning displaceability of alveolar crest mucosa, Experimental research, Shika Gakuho, 72 (6): 1043~1071, 1972 (Japanese)
5. Ono T. et al. Changes of the mucous membrane under loading of complete denture, J Aichigakuin Univ. 1991; 29: 435 – 443 (Japanese)
6. Miyashita K.. Mobility in function of maxillo-mandibular complete dentures, J. Stomatol. Soc. Jpn, 1997;64(2): 223 – 242 (Japanese)
7. Someya S. et al. Remount technique of Complete denture, J Nippon Dental Review,

- 1978;427: 25 -41 (Japanese)
8. Mizokami T. et al. Gothic Arch tracing method combined with tapping point recording in clinical cases of edentulous jaws and its advantage, Dental Diamond, 1985: 10: 246-257 (Japanese)
 9. Murakami Y. et al. Quantitative evaluation of Gothic Arch and Tapping Point in edentulous patients, Shigaku, 1992: 80 (4): 783-808 (Japanese)
 10. Tanaka H. et al. Clinical characteristics of temporomandibular joint disorders in complete denture wearers – Occurrence frequency of TMJ internal derangement, J the Japan Prosthodontic Society, 1995: 39 (2): 396-405 (Japanese)
 11. Abe S. et al. Changes in morphology of Temporomandibular joint after tooth loss that are essential to know in dental practice, J Nippon Dental Review, 2001:61(4): 97 – 100 (Japanese)
 12. Saito Y. The Statistic Analysis of Gothic Arch Records with Tapping Point when Taking the Maxillomandibular Registration for the Complete Denture - The Relation of the Tracing between the Quantitative Evaluation and the Morphological Evaluation by the Gothic Arch Score, J. Acad. Gnathol. Occlusion, 2009: 29 (4): 252 - 265 (Japanese)
 13. Saito Y. Diagnostic significance of Gothic Arch tracing, J Practice in Prosthodontics 2010: 43(1): 39 – 53 (Japanese)
 14. Suzuki K. et al. A study on the numbers of denture adjustments in complete denture wearers – Relationship to stability of tapping point, J the Japan Prosthodontic Society, 2001: 45 (1): 106-116 (Japanese)
 15. Mitani H. Partial denture for dental students, Tokyo: Ishiyaku Publ. 1983. 113 (Japanese)
 16. Abe J: Lower complete denture suction that anyone can get, Tokyo: Hyoron Publ., 2001 (Japanese)
 17. Glossary of Prosthodontic terms edited by the Japan Prosthodontic Society, 2nd ed. Ishiyaku, Tokyo, 2004. 83 (Japanese)
 18. Saito Y. Lingualized artificial teeth and bilateral balance for complete denture, J Dental Diamond, 2007: 32 (12): 131-141 (Japanese)

19. Kawara M. How to climb a mountain of complete denture, Tokyo: Ishiyaku Publ. 2009. 154 (Japanese)
20. Abe J. Magnitude of clearance in the anterior region and displacement immediately after complete denture insertion, J Practice in Prosthodontics, 2009: 42(5): 552 – 563 (Japanese)

【End】